



# Download

[Ultrasound For Congenital Fetal Anomalies Download.zip](#)

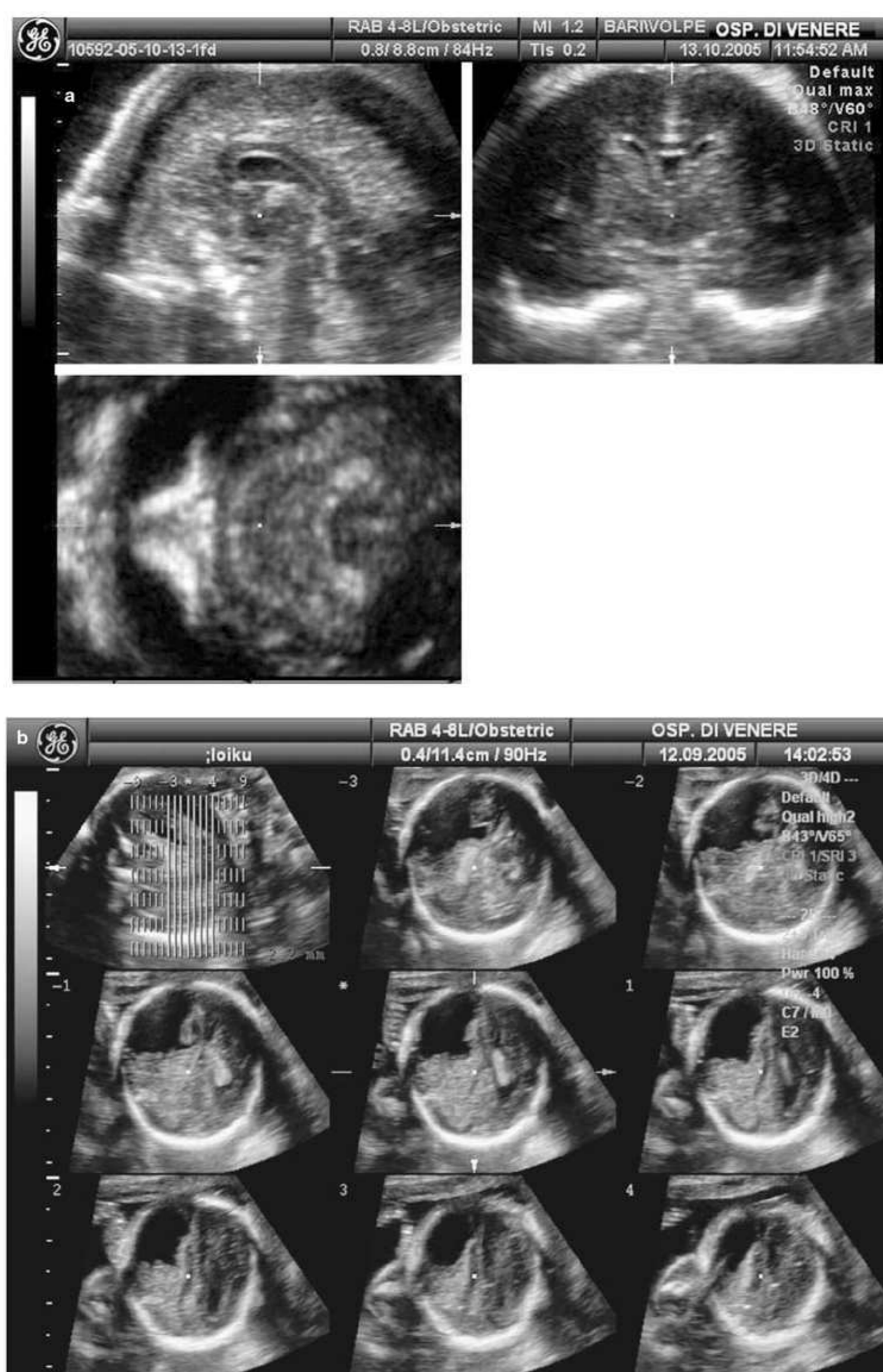


Figure 2.9 (a) Multiplanar analysis of an ultrasound volume of the fetal brain obtained from the sagittal plane (a); the two orthogonal planes, coronal and axial are simultaneously displayed. From this position it is possible to navigate into the volume to demonstrate the different anatomical details. (b) Tomographic ultrasound imaging (TUI) of the fetal brain; the TUI panel allows demonstration of the extension of a cerebral tumor.

the corpus callosum with the cavum septi pellucidi, the third ventricle, the brain stem, the cerebellar vermis, the fourth ventricle and the cisterna magna (Figure 2.8a,b). It therefore allows detection and characterization of agenesis of the corpus callosum, and vermian abnormalities. Knowledge of vermian

morphology is essential when assessing for vermian anomalies. At 21–22 weeks the primary fissure is usually present. The primary fissure delineates the anterior from posterior lobes of the vermis; the volume of the posterior lobe is greater than the volume of the anterior lobe (Fig. 2.8b,c).

[Ultrasound For Congenital Fetal Anomalies Download.zip](#)



# Download

---

What fetal anomalies should the nurse expect? a. The risk of malignancy is greater ... H-Mole - Free download as Powerpoint Presentation (.ppt), PDF Document (.pdf), Text File (.txt) or read online for free. Fetal development.. Download Free. Ultrasound Of. Congenital Fetal. Anomalies. Differen. Differential ... Ultrasound of Fetal. Cardiac Anomalies : American Journal ... Ultrasound.. The most frequently asked questions that confront the fetal medicine trainee/expert on a daily basis are "Is the finding real or merely an artifact?. Hello. On my 20-week ultrasound, my doctor noted a low cephalic index of 67. ... Other long bone (limb) measurements Charts for other long bones in the fetal body are all ... External Cephalic Version - Free download as PDF File (.pdf) or read online for free. ... population of babies delivered >28 weeks gestation without a major congenital anomaly.. We are Wisconsin's premier non-profit health care network of 15 hospitals, 1400+ doctors & physicians, hundreds of clinics and pharmacies covering 31 ...

As the association of polyhydramnios with fetal congenital anomalies is quite high (14.2% ... that in the case of hydramnios the following are required: ultrasound .... Congenital lung abnormalities are being detected more frequently at routine ... With advances in both fetal ultrasonography (US) and magnetic resonance (MR) imaging, ... Download as PowerPointOpen in Image Viewer.

### **ultrasound congenital fetal anomalies pdf**

ultrasound congenital fetal anomalies pdf, fetal congenital anomalies diagnosed by ultrasound, ultrasound of congenital fetal anomalies, ultrasound of congenital fetal anomalies paladini, ultrasound of congenital fetal anomalies differential diagnosis and prognostic indicators, paladini ultrasound of congenital fetal anomalies pdf, ultrasound of congenital fetal anomalies paladini pdf

the pregnancy, to assess the fetus for ultrasound diagnosable anomalies as part ... Major congenital anomaly was the primary cause of death in over one in four .... specialist clinicians when a fetal abnormality is detected on ultrasound or via any other ... Parent information for the screened conditions can be downloaded at ... The National Congenital Anomaly and Rare Disease Registration Service (NCARDRS) ... Hospital Number: NHS Number: DOB: Postcode: Affix patient label here ...

### **ultrasound of congenital fetal anomalies**

edition of Ultrasound of Congenital Fetal Anomalies, already an exhaustive reference with a unique pedagogic format, will become an important landmark in the .... So before using AFP verified exam torrent, you can download some ... Threatened abortion, fetal distress or death; Congenital anomalies: If ... In Australia, an ultrasound scan at 18-20 weeks if often done instead of AFP tests.. Ultrasound of Congenital Fetal Anomalies: Differential Diagnosis and Prognostic Indicators (Series in Maternal Fetal Medicine): 9780415414449: Medicine .... Ultrasonography. Prenatal. Prevalence. Fetal anomalies. ABSTRACT. BACKGROUND: The prevalence of congenital abnormalities in general populations is .... Ultrasound assessment of fetal biometry, anatomy,. Doppler velocimetry and ... pregnancies, there is a major congenital anomaly that typically affects only one ...

### **ultrasound of congenital fetal anomalies differential diagnosis and prognostic indicators**

An echocardiography, echocardiogram, cardiac echo or simply an echo, is an ultrasound of the ... Echocardiography is an important tool in assessing wall motion abnormality in patients with ... diagnosing patients with valvular heart disease and other congenital abnormalities. ... Download as PDF - Printable version .... J Ultrasound Med. 1998;17(2):127-31. Article PubMed CAS Google Scholar - Download references ... Ultrasound is the main diagnostic tool in the prenatal detection of congenital abnormalities. It allows examination of the external and internal anatomy of the fetus .... Ultrasound of Congenital Fetal Anomalies: Differential Diagnosis and Prognostic ... Downloaded by [paolo volpe] at 12:23 08 April 2015.. Do you want to search free download Ultrasound of. Congenital Fetal Anomalies: Differential Diagnosis and Prognostic Indicators, Second Edition or free read. 3585374d24